

fat and fibroglandular tissue

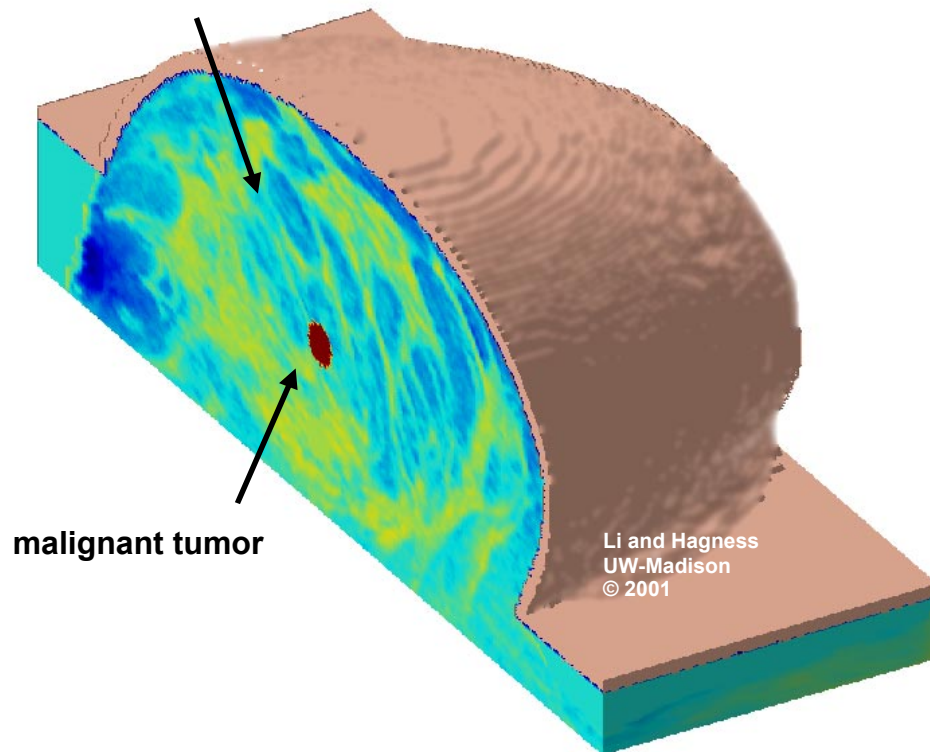


Fig. 8. Realistic breast-tissue model derived from high-resolution magnetic resonance imaging used in the ultrawideband pulse tumor-imaging study [8]. Source: X. Li and S. C. Hagness, University of Wisconsin–Madison.